

Reply to: *Arguments for and against movement at the spheno-occipital synostosis: Furthering the debate.* Richard Starkey (2015) International Journal of Osteopathic Medicine 18(2) pp102-115

© Andrew Cook MSc RCST October 2015-22: Version 3.1

Although written in a (usually) formal style, the response you are reading right now is ONLY privately published as a PDF file on my website:

<http://www.body-mind-resilience.com/>

Note : Starkey (2015) pointed out that the use of “SBS” is based on anatomical terminology no longer in current usage, and does not reflect the range of morphologies of the adult cranium. Therefore, in line with the suggestions in his paper, I have used the term “**clivus**” to describe the superior basilar superior surface, and “**SOJ**” (Spheno-Occipital Junction) to replace the generic term SBS. “Basilium” refers to the entire mass of bone extending between the sphenoidal sinus and the foramen magnum.

Also see [https://en.wikipedia.org/wiki/Clivus_\(anatomy\)](https://en.wikipedia.org/wiki/Clivus_(anatomy))

ABSTRACT

Background

The review of motion at the Spheno-Occipital Junction (SOJ) by Starkey (2015) makes

substantial reference to Cook (2005), and this letter is a reply to the points raised.

When describing cranial motion, anatomical complexity can obfuscate important general issues. Therefore, my intention here is to provide a pedagogical description of the motion of the cranium as simply as possible from which more specific details may be inferred by the reader in as much detail as they see fit.

Methods

Critical analysis of palpatory experience and osseous anatomy.

Conclusion

The SOJ is seen to be incapable of significant motion in a normal adult skull – from the point of view of (i) the mechanical behaviour of deformable structures, (ii) anatomical structure, (iii) protection of the foramen lacerum, (iv) comparative anatomy, (v) redundancy, and (vi) accounting for the direction of motion of the frontal bone and vomer when compared to motion of the greater wings of the sphenoid.

With no motion at the SOJ, all of the palpated motion of the external cranium (and that described by Sutherland) can be accounted for through normal anatomy and biomechanics, with no need for any additional “unknown” mechanisms.

KEYWORDS

Clivus, cranial motion, Cranial osteopathy, Craniosacral therapy, Cranial Rhythmic Impulse, CRI, Sphenobasilar synchondrosis, SBS, Spheno-occipital junction, SOJ, Spheno-occipital synchondrosis, Spheno-occipital synostosis, Vomer, William Sutherland, sphenoid, cranial sinus, sphenoidal sinus

1. INTRODUCTION

Starkey (2015) has provided an exceptionally clear and much needed summary of the current difficulties in reconciling cranial theory with the known properties of the Spheno-Occipital Junction (SOJ). He pointed out that my original paper (Cook, 2005) did not account for the possibility of a trabecular clivus, as proposed by Sumner & Haines (2011). This letter constitutes a reply to the questions raised in Starkey's review.

When describing cranial motion, it is easy to descend into pages of complex detailed anatomy and jargon, which can then obfuscate important issues. This is because – we can look at a motion or feel it, and understand it. But to *describe* that motion in exact detail without some visual aid is really quite difficult, and in the case of the cranial bones requires a detailed grasp of anatomy. Magoun (1951) devoted an entire book to this subject, and there is not space here to discuss Magoun's description of cranial motion blow-by-blow. So, rather than presenting a formal paper, my intention is to provide more of a pedagogical description of the motion of cranial bones with as little technical jargon or complex anatomy as I can get away with. It is hoped that the (relative) simplicity of the arguments presented will then make the more complex details self-apparent. I also urge the reader to not accept or reject the ideas presented here in a purely intellectual manner, but rather to look and feel and think for themselves by trusting their hands and going back to basic anatomy.

2. METHOD

The original position I started from in 2005 was to ask “***what would Sutherland have felt before he knew there was a cranial rhythm?***” This question takes us back before the concept of SOJ motion and “Sutherland lesions”.

At a very basic level, when palpated in a classic vault hold (cradling the occiput, with thumbs on the lateral aspect of the greater wings of the sphenoid), the cranium widens Left to Right (L-R). When palpated in an occipito-frontal hold, it can also be observed to slightly foreshorten antero-posteriorly (A-P). Thus, the motion called “*Flexion*” consists of the cranium becoming more rounded¹. And then it returns (“*Extension*”) to a more rugby-ball (or oblate spheroid²) shape. This global shape change is more fundamental than the detailed

-
- 1 I only realised this fully when I was calculating surface area-volume ratios for the vault to see how the Monroe-Kelly doctrine plays out – in an attempt to identify a physiological mechanism for the CRI. The frontal *cannot* move anteriorly as the parietals expand because that would create a large increase in volume – and therefore a large negative pressure in the skull (an impossibly large 25 metres of water column per loss of each cubic millimetre in volume). When I went back to palpation and was more careful to check A-P motion against L-R expansion, the cranial movements made a lot more sense.
 - 2 <http://mathworld.wolfram.com/OblateSpheroid.html> or

motion of a single bone (e.g. the sphenoid). So my view is that *we look at the motion of single bones by asking how they have to move in order to take part in and accommodate that generic motion* – i.e. an oscillation between being more spherical, to being more oblate.

To this I added AT Still's principle “*form follows function, function follows form*” (FFF)... The body is fundamentally intelligent, is self-optimising in health, and all structures truly reflect in their physical form both the normal physiological forces and everyday insults that they had to withstand. So the specifics of how each cranial bone accommodates *a generic change in sphericity* should be apparent in its form – both in the sutures (i.e. how it interfaces with adjacent bones) and structure (i.e. how much load it takes and in which directions, and where it displaces that load-). When related to bone, FFF translates as Wolff's Law³ – i.e. the size and shape of all bones comes about as a response to the magnitude and direction of their dynamic loading. This always applies to the central mass of the bone as well as its edges/sutures/joints. Historically, cranial texts have focussed heavily on sutures when investigating and describing cranial motion. And they tend not to question how the general morphology of the mass of bone may be expressing movement. Perhaps we can learn something by filling that gap.

In this process of observation, one has to carefully unpick five very different threads...

- i. pure palpatory experience
- ii. observed anatomical detail of both sutures and the structural properties of the cranial bones
- iii. known physiology (acknowledging that today's wisdom is necessarily incomplete and therefore may also be incorrect)
- iv. conscious and subliminal expectations based on pre-learned theoretical models
- v. clinical application of, and results derived from, certain techniques

3 Frost, HM (1994). Wolff's Law and bone's structural adaptations to mechanical usage: an overview for clinicians. *The Angle Orthodontist* 64 (3): 175–188, [available online](#)

3. OBSERVATIONS

Although all bone will deform under stress (as will steel or diamond), the degree of bending and deformation is dependent on the density, shape, thickness and composition of the particular object in question. When viewed structurally, according to the FFF principle, the cranium is a beautiful and elegantly engineered marvel of living, moving, vascularised bone, exquisitely adapted to the many demands made of it in a way that minimises weight. Wherever there is motion, there are lines of bend-ability (sutures, foramina, sinuses) or relatively flat and thin pliable expanses of bony plate. Wherever stress concentrates, the bony sections thicken and/or develop small radius curvatures and convergences of planes into rigid T-sections. Sutures exhibit a gloriously inventive range of morphological features so that the bony armoured sphere of the cranium can move freely and still retain a complete protective covering – a feature that was never achieved by even the most sophisticated of medieval armourers. Many parts of the skull are so thin as to be translucent, either because they are required to flex easily in all directions and/or they are protected by adjacent zones of strength and rigidity and so not subject to any substantial inter-osseous loading.

There are several ways to view any putative motion at the SOJ relative to the motion of the rest of the cranium ...

3.1 Visual inspection of structural forms

Q. What does the SOJ look like as a mobile structural unit within the context of surrounding anatomical structures?

The fact that the clivus is trabecular (Sumner & Haines, 2011) is something of a red herring, from two points of view.

Firstly, the clivus is, like most bones, a *composite structural sandwich*⁴ consisting of a lightweight trabecular (cellular) mass surrounded by an external tensile skin of compact bone. This composite structure provides a combination of deformational resilience, lightness and relative rigidity. And so it can be compared to any similar composite structure, including artificial wine corks, surfboards, internal soft car door handles, aircraft fuselage components, and the femur or hip or ribs. These are all bendable to some degree, but only under substantial force. To continue the surfboard analogy, we can observe a piece of surfboard (the clivus), attached to a piece of surfboard with the stiffening foam removed (the sphenoidal

4 Petras, A (1998) Design of Sandwich Structures. A dissertation submitted to Cambridge University Engineering Department for the degree of Doctor of Philosophy Robinson College, Cambridge, UK. <https://www.repository.cam.ac.uk/bitstream/handle/1810/236995/design>

sinus), and a much thinner extension on either side with a deep fissure cut into it (greater wings and superior orbital fissures).

Secondly, the SOJ must also be compared to immediately adjacent structures – because *under any applied mechanical force, the least rigid element will deform the most*. The clivus is a stubby (and therefore difficult to bend⁵) structure located directly posterior to the sphenoidal sinus (SS) and anterior to the foramen magnum (FM). The left and right superior orbital fissures (SOF) separate the left and right lesser and greater wings. When compared to these structures (SS, FM, SOF), the clivus can definitively be said to be rigid, just as the shaft of a feather is rigid when compared to its downy barbs or vanes.

In summary, my view remains that it is not the absolute strength of the SOJ that should be considered, but rather *its place in the structure of the cranium in both a local and global context*⁶. An excellent online resource showing the cranial sinuses is available from the University of Wisconsin⁷.

3.2 Protection of vulnerable vessels

Q. How is anterior-posterior (A-P) stress transmitted without risk to vital structures in the cranial base (considering the delicacy of the sphenoidal sinus and its anterior development into the ethmoid)?

It is possible to visually inspect the cranium for strong structures capable of transmitting A-P forces – both normal physiological and due to external pressure or impact. It would appear that (looking at the line of force from posterior to anterior) these must be transmitted in a Y-shaped path from the occiput, then connected centrally by the clivus, and then laterally to the outermost portion of the greater wings and the lateral aspects of the frontal bone (Figure 1). Posteriorly directed forces simply reverse this pathway. Of particular note are the trabecular, tetrahedral masses of bone on the greater wing tips, which engage with similarly massive tetrahedral elements on the lateral corners of the floor of the frontal bone. These receive remarkably little attention in descriptions of cranial motion, but their form clearly indicates that they are one of the major concentrations of stress in the cranium. Thus, the clivus is the stem of *the* Y-shaped major A-P load-bearing structure of the cranial base that is aligned

5 Bendability is partly to do with intrinsic strength and partly related to leverage. The deflection of a beam under load increases according to the fourth power of its length.

6 Seimetz, C. N.; Kemper, A. R. & Duma, S. M. (2012) An investigation of cranial motion through a review of biomechanically based skull deformation literature. *International Journal of Osteopathic Medicine*, 15(4): 152-165.

7 See: Interactive Sinus Anatomy, University of Wisconsin: Normal Sphenoid.
<http://uwmsk.org/sinusanatomy2/Sphenoid-Normal.html>

roughly halfway between the coronal and transverse planes. It is interesting in this respect that the greater wings are standard contact points during cranial work. It could even be said that an interest in physical motion of the sphenoid is actually an interest in the distribution of forces through the cranial structures.

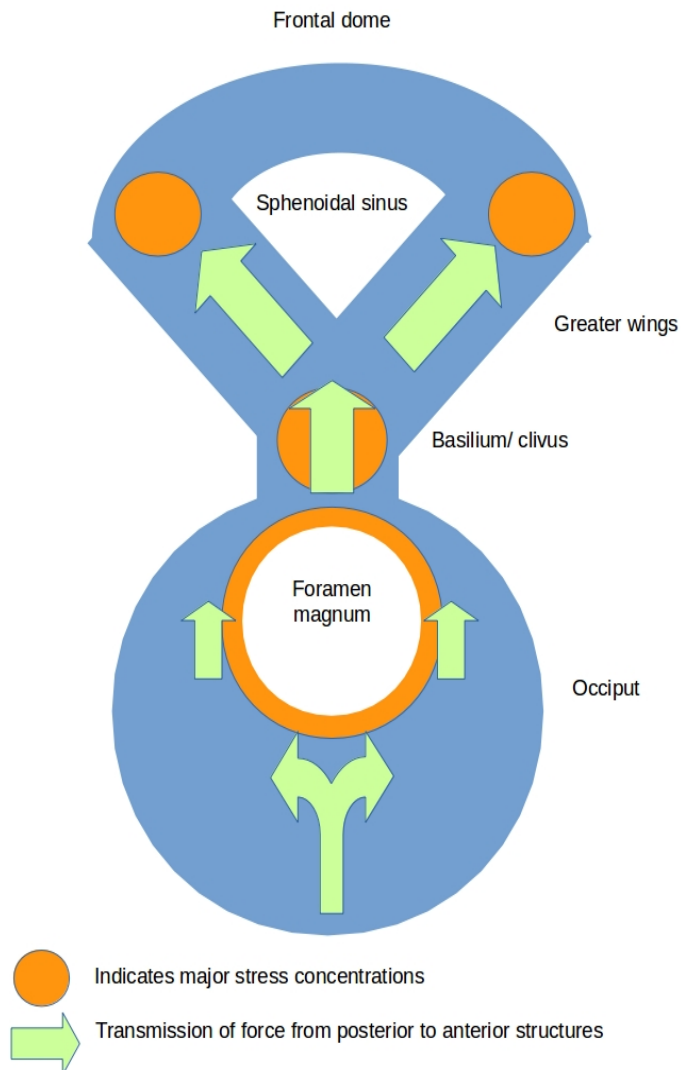


Figure 1 : structural arrangement of the cranial base

Much more can be said about the transfer of structural forces, and some detail was provided in Cook (2005). An accurate finite element structural model would be a very useful addition to this debate. These have been developed over the past few years to investigate forces in both human and animal skulls, their resistance to impact, and the mechanics of the jaw^{8,9}. The basilium is the only central structure in the cranial base capable of transmitting A-P forces. All other connecting surfaces are either quite thin and/or contain important foramina. With a mobile SOJ or substantially deformable clivus, the cranial base becomes vulnerable to closure from external forces. Whereas a rigid

- 8 Viviana Toro-IbacacheV, Fitton LC, Fagan MJ & O'Higgins P (2015) Validity and sensitivity of a human cranial finite element model: implications for comparative studies of biting performance. *Journal of Anatomy*. Article first published online: 23 Sep 2015. DOI: 10.1111/joa.12384
- 9 McCurry MR, Evans AR, McHenry CR. (2015) The sensitivity of biological finite element models to the resolution of surface geometry: a case study of crocodilian crania. *PeerJ* 3:e988 <https://dx.doi.org/10.7717/peerj.988>

clivus protects otherwise vulnerable structures – particularly the foramen lacerum and the cavernous sinus. Inspection of a hand specimen is useful in forming your own opinion on the validity of Figure 1 and the above commentary.

3.3 Redundancy

Q. Is motion at the SOJ necessary to ensure that palpated cranial motion really occurs?

The answer is – no. And this can be tested by anyone with a little time and a disarticulated skull to play with. The more pliable sections of cranial bone and the sutures and foramina, plus the sphenoidal sinus, provide a capacity for motion which exactly matches the palpated cranial motion *without the need for motion of the SOJ*. Most of these were described in tedious¹⁰ detail in Cook (2005). But they can be far more easily and pleasurably worked out from first principles by critical observation of the anatomical detail than can be read in a dry publication. In particular, the greater and lesser wings of the sphenoid can converge during Flexion by temporary partial closure of the SOF; and the anterior rostrum is far less capable than the clivus of resisting force due to the extreme thinness of bone surrounding the sphenoidal sinus.

You might also like to inspect the clivus and look for physical signs of hinging, bending or other deformation (under the FFF principle). There are none – which is rather a difficult puzzle for any arguments in favour of a mobile SOJ. This is not an absolute indication of immobility, because the parietal surfaces flex during the CRI, show no obvious external signs of regular motion, and are also composite structures of compact bone with a trabecular core. But the parietal surfaces are far thinner than the clivus and lie in between less pliable (rather than more pliable) zones.

10 Frankly, I find myself zoning out after several paragraphs of anatomical description of motion, and suspect that most other people do the same. It is far easier to observe motion and to feel it – rather than attempt to describe it, or infer what someone else is saying by just reading a description. Hence the sustained attempt here to keep specific descriptions to a minimum.

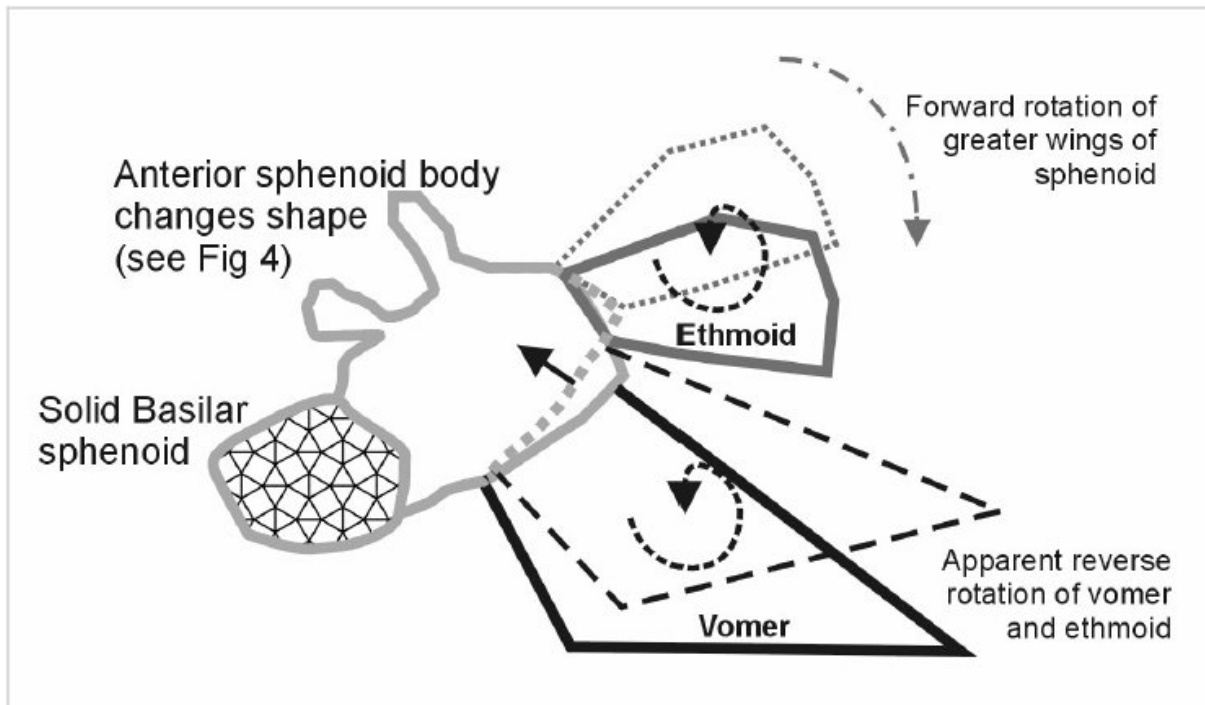


Figure 2: The solid clivus and the flexible sinus result in a change in angle of the vomer. Lateral view of the sagittal plane, schematic only. Solid lines show Extension, dotted lines show Flexion. from Cook (2005)

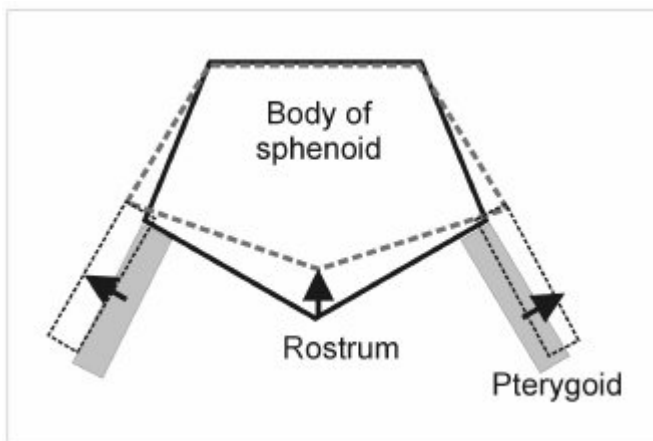


Figure 3: Anterior view (coronal plane) of deformation of sphenoid sinus from Cook (2005). Dotted line shows position during Flexion.

3.4 Contradictions

Q. How does the palpated relative counter-rotation of the vomer and the greater wings (of the sphenoid) take place?

It is reasonable to assume that the clivus is rigid when compared to the sphenoidal sinus, the sinus being hollow. Given this configuration of solidity and compliance, the relative motion of the sphenoidal greater wings and rostral surface/vomer will conform to their familiar palpated “meshed gear” motion. This was shown in Cook (2005) and is caused by the collapse of the anterior rostrum into the sinus on Flexion, which changes the rostral angle against the unyielding posteriorly lying clivus (Figure 2). Unfortunately, this latter principle cannot be inferred from moulded skulls because the casting process does not reproduce a hollow sphenoidal sinus.

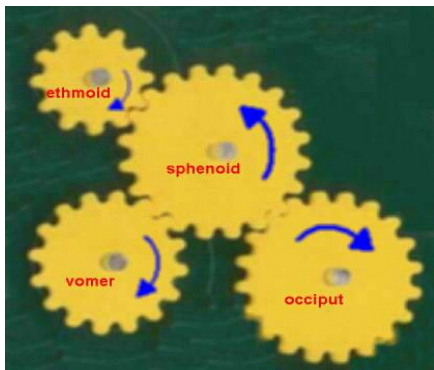


Figure 4: The traditional meshed gear description of anterior vault motion. Yes – it describes the palpated motion along the sagittal plane, and we all know that there are no gears, but have we really asked why these four bones move in this way? And what happens to the frontal bone?

Since there is *not* a meshed gear at the rostrum, there ceases to be a rational explanation for the motion of the vomer if the SOJ moves to any significant degree. Therefore, any model of cranial motion that requires the SOJ to be mobile also has to provide an *anatomically realistic* way that the vomer might counter-rotate relative to the greater wings. So far, in 90 years of description of cranial motion, no such explanations have been forthcoming.

Q. Why is it that the Frontal bone does not move anteriorly on Flexion?

In a healthy fully mobile cranium the frontal and occipital surfaces can be felt to foreshorten slightly during Flexion¹¹. Given a flexible or hinging SOJ, the sphenoid will arc inferiorly and slightly anteriorly. The anterior component of motion is required because the body and wings sit slightly superior to the SOJ. If the Cranial Rhythmic Impulse (CRI) includes a

11 This A-P foreshortening on Flexion of a surface-area-conserved ellipsoid can be calculated to be about 20% of the lateral (parietal) expansion, which matches the palpated experience. I have not presented these calculations to preserve simplicity. Equations for surface area and volume of an ellipsoid can be found at <http://mathworld.wolfram.com/Ellipsoid.html>

mobile SOJ which truly flexes, then an anterior motion during Flexion of *both* the body *and* greater wings of the sphenoid would also push the frontal bone along the same arc. It would also drag the parietals forwards, and in so doing the parietals would be drawn together laterally. On the other hand, the *palpated* expansion of the parietals during Flexion with a simultaneous (small but nevertheless detectable) A-P foreshortening of the cranium are exactly what one would expect from a rigid clivus and a deforming sphenoidal sinus with closure of the SOFs.

Q. How can the greater wings move as part of a complex intermeshed structure?

The whole of the vault can be likened to an ellipsoid (a sphere lengthened slightly on one axis, like a stubby rugby ball). It is not possible to stretch compact bone like an elastic band, so the ellipsoid of the cranium has a more or less constant surface area as it deforms through a Flexion-Extension (F-E) cycle; becoming more spherical during Flexion and more lengthened A-P during extension. Although there is some loss of surface area during Flexion as the SOFs close¹². A simple experiment with a hula hoop (imagining that this is a thin transverse section of the cranium through the eye sockets) will convince you that - if the SOFs do not comply - it would be impossible to feel any substantial anterior A-P motion of the sphenoid greater wings during F-E. Simply mark the greater wings on the hula hoop and then wrestle with it in an attempt to reproduce their palpated motion relative to the frontal and occipital bones. (Hint : Instead of the greater wings physically moving into a gap, they would be restricted to lying on the surface of a simply deforming ellipsoid, so don't waste too much time on this. Removal of a short section out of the hula hoop to simulate the SOF gap and sphenoidal sinus helps the greater wing motion and reduces the need to wrestle.)

On the other hand, if the SOFs close during Flexion and the sphenoidal sinus collapses, then we can easily account for the both the magnitude and direction of palpated excursion of the greater wings. The A-P dimension of the cranium is also able to shorten due to approximate conservation of surface area and the forces that applies on the frontal, cribriform plate and anterior aspect of the sphenoidal sinus (described in more detail in Cook, 2005). Furthermore, if the SOFs comply, then this goes against motion of the SOJ on grounds of the mobility vs. rigidity argument above.

12 A simultaneous change in overlap area of the gill-like suture on the posterior and superior edges of the temporal squama is harder to qualify. I estimate that on balance a decrease in the parietal overlap during Flexion is the greatest change, thus the parietal surface area change slightly ameliorates the loss of surface area caused by closure of the SOFs. The relative contributions to non-conservation of surface area due to changes in parietal overlap and closure of the SOFs would be a useful topic for anatomical study, because they have a hard relationship to the volume of CSF during the F-E cycle, and therefore to mobility of the vault, and therefore to free expression of the CRI.

3.5 CRI dependency on SOJ motility

Q. Is motion at the SOJ necessary for the CRI to exist?

Here I would like to refer to comparative anatomy. We know that there is a strong CRI in animals. But (in contrast to the human membranous falx and tentorium) in most animals the falx and tentorium are naturally ossified. This creates an extremely rigid cranial structure, capable of resisting the strains imposed by far stronger jaw muscles, with reduced capacity for motion throughout the cranium. So for the human CRI to be dependent on generic cranial motion (including motion of the SOJ) would place humans in a unique and inexplicable position that the human mechanism for the CRI is different to that for the rest of the animal kingdom.

3.6 Missing mechanisms

Here we come to the perpetual problem that it is intrinsically difficult to separate the nature of cranial motion from the mechanism driving the CRI.

Q. By what means might the SOJ be the primary source of motion?

This question is necessary because despite all of the above remarks, if the CRI is driven from the SOJ, then SOJ motion would be an *a priori* from which all other motion must follow. Any purported *physical* motion emanating from the SOJ must arise either (i) from the clivus itself or (ii) from the membranes and vessels specific to the surface of the clivus *and nowhere else*. This latter exclusion is necessary because if (putative) motile membranous forces do arise elsewhere, the natural pliability of non-SOJ structures will (again) ensure that the SOJ remains relatively immobile. A review of potential candidate physiological mechanisms¹³ that might cause the CRI at the SOJ only - reveals no such known beast.

If trabecular structures themselves are motile, then it is relevant that the clivus possesses the largest trabecular mass in the cranium - but again, no such motility is known. And if we consider infants whose cranial bony structures are still in membrane and cartilage with separate ossification centres, we still palpate a rhythm. Thus, the presence of a trabecular clivus is not a precondition for the CRI. Similarly, vasomotion of the dense venous bodies on the surface of the basillium or of the cavernous sinuses cannot strictly be invoked to produce the CRI uniquely at the SOJ. As far as we know, the valveless cranial veins (and all

13 Ferguson, A (2003) A review of the physiology of cranial osteopathy. Journal of Osteopathic Medicine 6(2) pp74-88, with comment by Leon Chaitow.
<http://faculty.une.edu/com/jnorton/PDFfilesCranial/CranialPhysiology.pdf>

intraosseous veins, as might be found in the clivus) do not express vasomotion^{14, 15, 16}. But vasomotion *does* occur throughout most of the rest of the body, so if it is the source of the CRI, the cranial effect is a general membranous one (rather than being confined to the area of the SOJ). In the case of venomotion there is only one glimmer in this that might support Sumner and Haynes's model. That is – if the dense venous bed on the clivus, the intercavernous (circular) sinus, invests the trabecular clivus with a capillary network that *does* express vasomotion. Even if this is the case, we are still left with the paradox that cranial motion can be explained purely by flexing the external cranial bones in their most labile manner. Therefore, any motion arising of and from the SOJ would not usually be the greatest component of palpated motion.

Another possible candidate for a cause of the CRI is the Mayer wave^{17, 18} - an oscillation in arterial pressure, taking place over about 10 seconds¹⁹. The Mayer waves appear as change in sympathetic vasomotor tone of arterial blood vessels. Their cause is somewhat ambivalent, and may have contributions from *both* the baroreflex loop (pressure feedback within the vascular system) and a central oscillator in the brainstem. Their relationship with heart rate variability is also significant in that there is clearly some feedback to/from mental-emotional states (see research by Rollin McCraty at HeartMath). If driven by the Mayer wave, the CRI could occur through changes in membrane tension (i.e. membranes mechanically connected to arteries) through the whole body and/or specifically in the dura. So we have the superficial temporal and the occipital arteries strongly bound to the dura of the upper vault. The CRI can also act independently in the face (maxillary and facial arteries). In the floor of the cranium the carotid artery passes through a channel in the medial temporal fossa, which is directly adjacent to the clivus/SBS and could (from a palpatory point of view) potentially be confused for the SBS itself. We have several arteries entering the sacrum, particularly the lateral sacral artery and middle sacral artery, and of course the anterior and posterior spinal arteries that attach to the spinal cord itself. Generally speaking the CRI is coherent – i.e. its frequency and phase is consistent throughout the body. But that is not always the case – it being quite common to find the CRI out of phase between occiput and sacrum if there is inflammation around any of the spinal nerve roots in between. So a change in arterial vasomotor tone is a

14 Farasyn, A (1999) New hypothesis for the origin of cranio-sacral motion. *Journal of Bodywork and Movement Therapies* 3(1) pp229-237 doi: [http://dx.doi.org/10.1016/S1360-8592\(99\)80009-6](http://dx.doi.org/10.1016/S1360-8592(99)80009-6)

15 Farasyn, A & Vanderschueren, F (2001) The decrease of the cranial rhythmic impulse during maximal rhythmic exertion: an argument for the hypothesis of venomotion? *Journal of Bodywork and Movement Therapies* 5(1): 56-69 doi: <http://dx.doi.org/10.1054/jbmt.2000.0204>

16 Farasyn, A (date?) self-published slide presentation http://www.roptrotherapy.info/CRANIOSACRAL_%20THERAPY.pdf

17 Michael G. Z. Ghali1 & George Z. Ghali1 (2020) Mechanisms Contributing to the Generation of Mayer Waves. *Front. Neurosci.*, 10 July 2020 | <https://doi.org/10.3389/fnins.2020.00395>

18 Claude Julien (2020) An update on the enigma of Mayer waves, *Cardiovascular Research*, Volume 116, Issue 14, 1 December, Pages e210–e211, <https://doi.org/10.1093/cvr/cvz327>

19 Otherwise known as "Traube–Hering–Mayer waves" (or some other combination of the three names)

pretty good candidate for the CRI. Again, it may be that the capillary bed in the clivus exhibits some kind of mechanical motion due to arterial vasomotion. However, the totality of arteries connected to the dura and other structures in the craniosacral system would far outweigh that contribution to motion, and a single source of motion for the CRI does not explain its occasional asynchronous (incoherent) behaviours throughout the rest of the body.

In summary, if we adopt a position in which the SOJ is rigid, then all of the phenomenological range of palpated CRI motion may be explained using a modern medical understanding of anatomy, physiology and biomechanics. On the other hand, a mobile clivus presents paradoxes which require additional “unknown” mechanisms to be invoked and which require explanations for palpated motions to be clarified.

4. MORPHOLOGY

4.1 Historical changes?

With regard to the morphology of the SOJ, I have to bow to the definitive and thoroughly researched review carried out by Starkey (2015). The descriptions in Cook (2005) were based on viewing a small number of disarticulated specimens. I would point out that Starkey’s sources could be subject to an intriguing interpretation – namely that the age of ossification of the SOJ appears to have gradually decreased over the past 100 years in medical textbooks. Yes, this may be just an improvement in observation. However, sutures remain patent and open when they are subject to motion and stress, and close when there is no longer a need for them to move.

So it could also be that the degree of stress applied to the whole vault by the general human population has declined over time, maybe due to changes in diet or lifestyle. For instance, tougher food requires far more power in the temporalis and other masticatory muscles and so places greater strains on the cranium, resulting in greater stress variations at critical parts of the structure. It also creates a far stronger and wider faciomaxillary structure²⁰ – one more familiar in photographs of faces from “third world” countries where young children are not fed as much pap or sweet foods and are allowed (or have no choice but) to chew on tough foods. Similarly, greater physicality in life in the 19th and early 20th century (horse-riding, manual labour, less time sitting in front of a TV) would result in greater musculature of the body, which itself will place greater strains on the cranium via attachments of the trapezius, SCMs, scalenes, spinalis, sublinguals, thoracic inlet muscles and other smaller muscle groups.

This change in physiological demography over the past century in the western world is a

20 <https://www.youtube.com/watch?v=tVjMgVClYPA&feature=youtu.be>

major issue when translating traditional or “classical” Osteopathy into a modern context. What rhythms and motions did Sutherland feel when he worked with his client base in the 1920's and 30's, and was that different from the cranial motions typical in a 21st century client base? How does that change affect the clinical application of cranial techniques?

4.2 The normality of cranial motion

Thinking in more general terms... the skull has to deform under stress – of any kind – because all physical structures deform. And it would be extremely odd if cranial motion did not use the same deformational processes as any other normal physiological strain due to (e.g.) muscular activity due to mastication or heavy loading of the neck muscles. Simply put, ***the cranium will naturally accommodate external or internal stress how it moves most easily.*** The form of the mass of bones and the sutures (as determined by Wolff's Law) is therefore unlikely to be unique to cranial motion. Rather, it is indicative of a generic compliance of the cranium to applied mechanical stress from whatever source.

5. CLINICAL APPLICATION

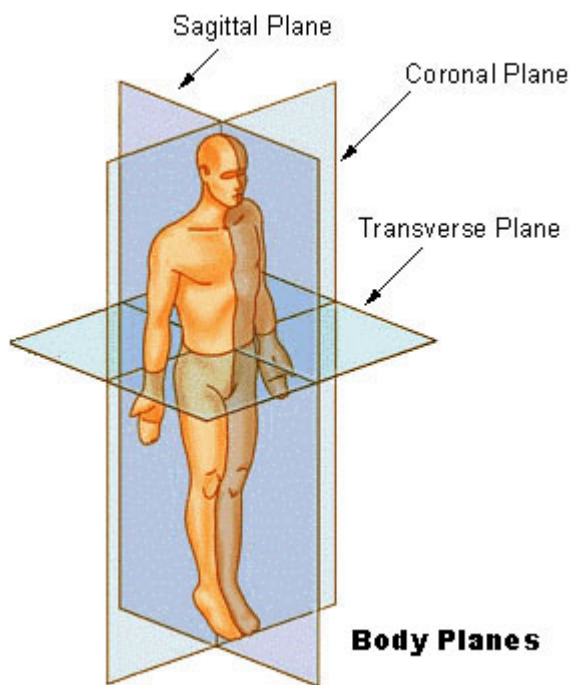
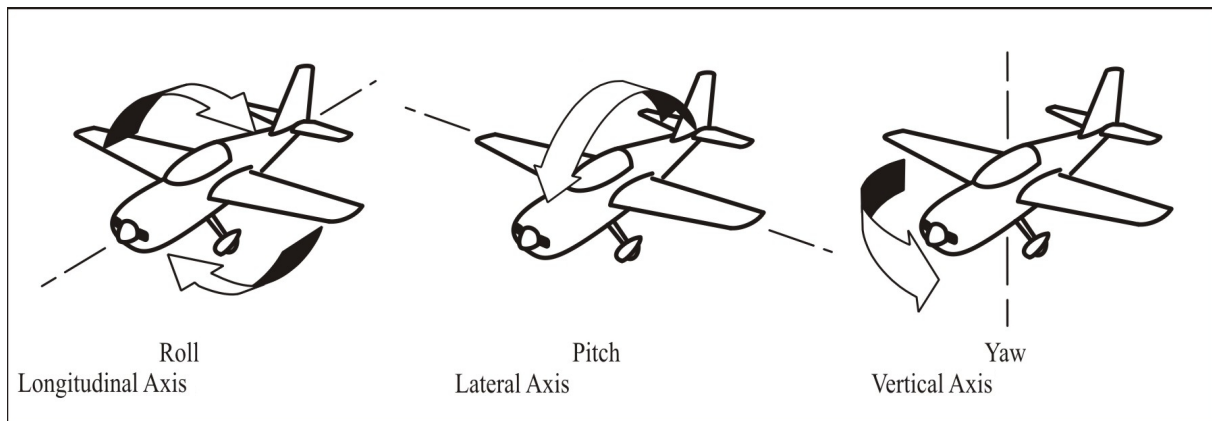
5.1 Origins of the Sutherland Lesions

I would like to speculate that Sutherland originally highlighted the SOJ precisely because everything else moves round it. In the complexity of the motions of the vault, a single universal-joint-like frame of reference in a central location is a useful aid to visualisation and also a usefully simplified way of conveying complex motions and principles when teaching. This possible origin of the Sutherland Lesions is implied by the quotations from Sutherland that Starkey (2015) has so usefully compiled.

If anyone wishes to describe position in three dimensions, then we simply use a coordinate system {x,y,z}. Complex motion in three dimensions requires more information, because motion may be *transitional* (a sideways displacement) or rotational (around an axis). Furthermore these have to have a common frame of reference to make any sense. So we take the three orthogonal²¹ axes (y=up-down, x=left-right, z=front-back), and these give us directions of displacement and axes of rotation relative to a common origin. When comparing two features (bones), then it is the *relative* motion that has meaning ... so if both of them rotate round the same axis or move in the same direction by the same amount, there is no effective change for that pair. Therefore we have to think about *relative rotation* and shear

21 “Orthogonal” means perpendicular, or at right angles – like the three faces of a cube meeting on one corner.

(i.e. *relative displacement*). There we have it – three rotational axes, three planes of shear... is this starting to sound familiar?



So the Sutherland lesions are the most logical and simple means to describe complex deformations three dimensions. And as an origin, Sutherland chose the SOJ. This orthogonal system is interestingly relevant to the set of neural fibres of the brain discovered by neuroimaging research at UCLA^{22, 23}. Also see discussion in the M tubes document²⁴.

Also, if the SOJ is a relatively solid structure, then its location central to the vault will naturally create a series of rotations with the SOJ as their centre (“Fulcrum”). When we deal with pathological tissue stasis this phenomenon is called “arc-ing”, and is a very familiar phenomenon in cranial work. It is

also a commonly recognised phenomenon in physics. For instance, the planets appear to move round the sun because the sun is heavier and therefore has more momentum. In reality the sun also moves round the planets – but the distance it wobbles as Jupiter and the other gas giants move in their orbits is relatively small. So we experience the sun as being fixed when actually, nothing is fixed in an absolute sense. The sun moves slightly in response to the planets, the SOJ moves slightly in response to stresses from elsewhere in the cranium. But the overall impression of both, due to the ratios of inertia or stiffness, is that they are centres of rotation.

22 http://www.msnbc.msn.com/id/46897519/ns/technology_and_science-science/t/spectacular-brain-images-reveal-surprisingly-simple-structure/

23 <http://www.bbc.co.uk/news/science-environment-21487016>

24 <http://www.hummingbird-one.co.uk/pdf/MTubes.pdf>

5.2 Palpation

As Sutherland himself commented, it is only the *external* motions that we can directly palpate. I clearly understand the difficulty in this position, as I'm sure Sutherland also did when he used the word “imagine” to describe any sense of motion inside the cranium (see Starkey). Practising CST requires a little faith – in that motions are regularly “palpated” - or more accurately, “sensed” - deep within the head or body. In this case “imagination” is better described as a quasi-synaesthetic use of the sense of touch – which is almost impossible to convey to someone who does not have an experience of using their senses in this fashion. Probably the most important part of cranial courses is training students how to reliably access this mode of perception. It is definitely not imagination in the sense of “making something up”. If one proceeds with treatment *as if* these perceived motions are real, then the body responds. Therefore the most logical and simple stance to adopt is to assume that they are a trustworthy reflection of reality.

I would guess that some of the resistance to the idea of a non-mobile/motile SOJ is that this may bring into doubt the basic requirement in CST to trust palpation. *I disagree with this position*, because as practitioners we also know that the body is a hall of mirrors and will reflect back our expectations. I would suggest that the body has simply reflected back an expectation of a mobile SOJ, *and this does not invalidate any palpation that is not burdened with expectation and bias*.

5.3 Hinges, levers and other mechanical analogies

In the first edition of Magoun (1951), a fulcrum is described almost spiritually as “*the still point from which all healthy movement originates*”, **and which is displaced in cases of pathology**. *Magoun also freely considers the flexibility of the vault and states clearly that the idea of axes of rotation of individual bones (as a means to describe their motion) is a simplification of convenience that should not be taken literally because it can lead to conceptual problems*. Reading the book carefully, it is possible to observe him flipping backwards and forwards. On the one hand he describes a holistic 3-dimensional palpated/experienced living cranial motion. And then he is repeatedly brought back by a restrictive vocabulary to a description that is mechanical, rigid and based on hinges, levers and bones that are as solid in life as they are in death.

This is easy to write in hindsight, and it is also easy to envision the hundreds of hours that must have been spent in clinical observation, followed up by moving disarticulated bones relative to each other to find some clue to their motion in the living cranium. My guess is that

the mechanical language Still, Sutherland and their generation were steeped in made it difficult to fully re-join the conceptual dots all the way back from unmoving dead disarticulated bones they were looking at to the holistic flexibility of a living skull they were feeling. This is, indeed, a potential problem for *any* anatomist who bases their understanding of living, moving, breathing tissue on a detailed study of dead immobile tissue.

It is also possible that both Sutherland and Magoun were influenced by the writings of Huxley^{25, 26} - that used simplified 2-D models of the cranium to show the effect of cranial base morphology on the generic shape of the head. Of course, the rotational transitions possible for a 2-D sagittal model of the adult head do not translate so happily into 3-D shape changes due to the very rigid “design” of the frontal bone. Development of the skull at an embryological stage induces tensions and compressions that respectively create the flat plates and hard bony ridges of an adult skull, as the morphology responds to the forces imposed on it (“form follows function”). Either the morphology is shifted due to “abnormal” stresses at an embryological and developmental stage (usually pre-birth or peri-birth) or excepting the case of extreme impacts remains as-is but with “lesions” that are far more fulcra (abnormal restrictions of motion) than they are distortions of the bones of the vault. These two cases (adult lesions of motion vs developmental lesions of form, or inter- vs intra-osseous lesions) may require (and may be amenable to) quite different forms of intervention, and will be briefly discussed later in sections 5.4 - 5.7.

We therefore have a clear progression of Chinese whispers. From Sutherland defining cranial motion in the 1920's, and then refining his ideas and teaching to individuals and small groups, through to Magoun writing the first edition of “Osteopathy in the Cranial Field” in 1951. It would seem that the practitioners knew *up to this time* that bony motions could not be simplified in terms of pure axes of rotation, and indeed, Magoun warned against the dangers of so doing. But as soon as a description of cranial motion (including “Sutherland Lesions”) was in print, it was then available for misinterpretation. Unfortunately, Magoun focussed on sutures and used an analogy of fixed axes of motion as a means to convey motion as simply as possible, even though he directly acknowledged this was not a true picture. These axes were (at least initially) meant to be an approximation that made teaching and written descriptions easier. Textbooks following on, from that first edition right up to the present day, and the training programmes and teachers that rely on them, have mistaken the descriptions of axes of rotation for reality – and have produced beautifully drawn diagrams to show these rotations as if they are real.

25 Huxley TH (1863) Evidence as to man's place in nature. Appleton, New York

26 Antonio Di Ieva, Emiliano Bruner, Thomas Haider, Luigi F. Rodella, John M. Lee, Michael D. Cusimano & Manfred Tschabitscher (2014) Skull base embryology: a multidisciplinary review. Childs Nerv Syst | Review paper (2014) 30:991–1000 DOI 10.1007/s00381-014-2411-x

In reality the bones of the cranium *cannot* move in the way described by these books, because they would lock against each other. Individual bone motion can only be understood and accurately described in the context of

- its place in a global change in sphericity,
- the way that each bone is individually adapted to take part in that global change, and
- the way each bone dances with its neighbours.

In fact, once the principles of Wolff's Law are taken in, and some of the more important features of each bone are memorised, the complex motion pattern and the form of the sutures necessary to achieve that can more or less be worked out from first principles.

5.4 More on Sutherland Lesions

Another way that the Sutherland lesions are simplifications of more complex whole-body/whole-person patterns can be seen in the 2008 study by Timoshkin and Sandhouse²⁷. Here, 60% of the study population of largely healthy individuals had at least two of a Left Lateral Shear, Left Side bend and Right Torsion. This would produce a slight tendency for the entire vault to be parallelogrammed, with the Left eyebrow ridge forwards and down and the entire L side of the vault slightly forward relative to the right side. This common pattern can readily be seen in pictures of celebrities – e.g. John Prescott, Martin Amis, Colin Farrell, and is the most common presentation in infant plagiocephaly.

The other notable statistic in this study is that hardly any Sutherland lesions are “pure” - even in a healthy population sample, simple single lesions make up only 11% of the total. If one looks at the whole structure with regard to distortions, it is impossible for *one* of the bones to be displaced along any plane of shear or on any rotational axis without *all* of them being displaced or rotated or translated. This is a function of the interlocking nature of the sutures and solidity of the cranial bones (compression) and the continuity of the dura (tension), including tensile effects in major vessels and in the falx and tentorium.

27 Elena M. Timoshkin & Mark Sandhouse (2008) Retrospective Study of Cranial Strain Pattern Prevalence in a Healthy Population. JAOA • Vol 108 • No 11 pp652-6

5.5 Working with a rigid SOJ

So, if the SOJ is not undergoing literal planar and rotational translation, what is happening when we work with the CRI and Sutherland Lesions in a bony and fascial manner? I understand that this is no longer a fashionable mode of working, but

- a) sometimes the more subtle approaches finally resolve in membranous and bony motions which are best supported by switching attention to this physical level.
- b) Conversely, sometimes a more physical approach is demanded from the start by the body. More subtle (fluid etc.) contacts can then be used to clean up and complete integration.
- c) Historically, cranial work started on a bony and membranous level, and we are very definitely (amongst other things) bony and membranous beings. So it is just not possible to throw our hands up in feigned innocence and exclaim “oh – we don't do it that way any more” in an attempt to get round any need to explain anything.

The answer is somewhat multifaceted. However the main issue lies in the distinction between *inter-* and *intra-*osseous motion. The former relates to the relative motion of each fully formed bone in an adult skull. The latter relates to the imprint left in bones by abnormal or non-physiological forces as they were developing and ossifying. If these two components are unpicked during treatment, one can see that – with the exception of obvious adult head trauma – the Sutherland lesions largely relate to tension and torsion and compression patterns retained in the bony and membranous tissues from early developmental through to perinatal and infant stages...

5.6 Ossification sites and the neonate – why “SBS” techniques work

As is described in Cook (2005), the SOJ in the adult is incapable of any substantial motion (other than compression-decompression). And the vast majority of any movement palpated at the greater wings is due to the flexibility of the rest of the vault – particularly the anterior sphenoid, and particularly due to the compliance of the superior orbital fissure. However, I strongly believe that Sutherland one way or another knew what he was doing, even if his description was incorrect. And it would seem that a knowledge of ossification sites may give a better understanding of the SOJ and the Sutherland Lesions.

If one considers the neonate vault, we have various ossification centres that will fuse in the adult. e.g. the occiput is composed of four distinct bony sections::

1. the squama, which itself is even at birth a more or less fused mass of at least four proto-centres of ossification
2. the left condyle
3. the R condyle
4. the basilium, which includes about 1/3 of each condyle

During birth and in the 12-16 years prior to complete fusion of these distinct parts, the occiput may be affected by forces that cause interosseous lesions. i.e. the various sections may be pulled apart from each other or compressed against each other, or twisted or translated in any relative direction away from their “natural” relative seating *as individual bones*. Once the complete occiput fuses, remnant inter-osseous lesions become **intra**-osseous lesions (memories of these distorting forces). These continue to play out and affect the motion of the whole occiput (and everything attached to it), even though the lesion is now “contained” within a fusion of bone.

Similarly, at birth, the sphenoid consists of three major sections::

1. body (basilar portion), sella turcica and lesser wings
2. the L greater wing and pterygoid
3. the R greater wing and pterygoid

If one considers the vault to be in the same state that it is in at birth, the SOJ is a cartilaginous mass of very similar ilk to the cartilage that divides the different parts of any other unfused bone. And as such, it is capable of embedding interosseous strains as intraosseous strain-memories. These will continue to be present in the SOJ as a result of distortions to other more flexible parts of the sphenoid and its other cartilaginous divisions. Therefore, when working on sphenoid/SOJ lesions arising at birth or pre-birth, the Sutherland Lesions are completely valid; and so *in this situation (i.e. when working on intraosseous lesions in an adult sphenoid)* the SOJ should be considered as a cartilaginous joint capable of moving and also capable of containing a lesion.

However, for lesions arising from neonates through to teenage years in which the SOJ and sphenoid have **not yet** become relatively immobile or fused, they (along with the entire vault) can also be viewed considering individual ossification centres- i.e. the various bones are composed of distinct freely floating elements. From this point of view, the SOJ is just one site of interosseous mobility in a complex jigsaw, and if there is a lesion at the SOJ there will inevitably be a lesion elsewhere on the sphenoid and probably at other sites. In this case, it is better to consider the whole bony cranium as being a fluid or gel. But the SOJ still remains *at*

the centre of any motion by virtue of its position and its importance in transmitting stress A-P through the cranial base.

For lesions arising after puberty (i.e. known major trauma from e.g. car accidents, cage fighting, extreme ironing, minor family feuds, etc.), the SOJ is a fulcrum and position of stability, so it is particularly useful to recognise that lesions are generally going to be held elsewhere. However, it will still hold and mirror the strain patterns that result from the peripheral lesions.

So – in some ways it makes sense to drop the idea of Sutherland lesions as being **only** relevant to the SOJ, and instead use them as a systematic means to access the entire reciprocal tension jello system... three orthogonal planes, three orthogonal axes, back to cartesian space. In fact, what becomes apparent from this working analysis is that the Sutherland Lesions were probably his initial step towards work with fluid. Treating the SOJ as a flexible joint is in effect taking it back to the time when it was a flexible and fluid joint – a time before the adult cranium had been fully ossified.

5.7 So how to treat?

Well, this is just a suggestion.

- Taking Magoun literally and considering that the SOJ is a Fulcrum and “*the still point from which all healthy movement originates*” (and which is displaced in cases of pathology), we would be interested in the stillness at the SOJ as a powerful force of self-correction.
- From this stillness, the Sutherland lesions define the way in which the cranial vault is holding the Fulcrum off-centre and/or the way that the Fulcrum is held off-centre by internal forces.
- From here we can (to take just two possibilities) either use the Sutherland Lesions as a map with which to navigate membranous and bony lesions around this Fulcrum, or we can ignore them and focus on the relationship between the fluid aspect of the bones/membranes and the central Fulcrum.

The use of indirect rather than direct technique is required by the complex intermeshed sutures in an adult, and by the way that stress in the SOJ mirrors peripheral strain. My experience working with infant heads is that a very delicate indirect motion (before following the usual direct pattern of motion) often makes the pattern resolve more easily. So really, with both infants and adults this is about providing sufficient looseness and play so that the self-

corrective mechanisms have room to work. Maybe there is also something about winding up the spring a little more so that there is more self-corrective energy, but that viewpoint may well be a little too mechanical in most circumstances.

5.8 Further philosophifications

5.8.1. Time and focus

Speaking personally, the main question that arises here is – how far do we go back? If we already have chosen to go back to a time perinatal or pre-birth where ossification sites have not yet finished their journey to meet each other – why stop there? Why not go back even further?

Taking this question to its two possible extremes... Is there virtue in working with structures as close to their present form as possible, in acknowledgement of what is NOW, or is there a benefit to connecting with the primordial one-ness from which they arose? Or do both have their place? Or can we do both at once? Or something less extreme? My personal preference is (wherever possible) to ask the question - “at what time/age was this XXX perfectly formed?”, and then to work from that point of health. However, there also seems to be merit in working more “mechanically” in many cases, finding the point of membranous balance. And some cranial systems seem to actively resist going anywhere but the here and now. I am unconvinced that there is a “best” technique of working with these – but rather what Sutherland termed “the Inherent Treatment Plan” (ITP) is the final arbiter. This has an intelligence of its own, and may demand attention on many different levels, or may be ambivalent as to “how” and far more interested in adapting whatever skills are offered by the practitioner to its own ends. As I have read around the classical osteopathic origins of Craniosacral Therapy over the past few years^{28, 29}, I have realised that Osteopathy (and Cranial Osteopathy) were originally applied on the most severe of medical cases. As such, the idea of there *not* being a formal treatment plan in these cases becomes almost unthinkable. It must have taken an extraordinary leap of courage and faith to realise that the needs of the body are capable of being expressed *Inherently*, even in the most extreme of situations.

All one has to do is listen.

28 Lewis, JL (2012) A T. Still: From the Dry Bone to the Living Man. Publ. Dry Bone Press. Hardcover, 384 pages. ISBN-10: 0957292708, ISBN-13: 978-0957292703

29 Fuller, DB (2012) Osteopathy & Swedenborg. Hardcover: 622 pages. Publisher: Swedenborg Scientific Association Press; 1st edition. ISBN-10: 0910557829, ISBN-13: 978-0910557825, available at http://www.swedenborg.org.uk/bookshop/related_titles/osteopathy_swedenborg

5.8.2 The Map is not the Territory³⁰

Many cranial authors after Magoun's first edition (1951), have made the mistake of taking theory and attempting to (literally) bend the anatomy to suit it. Indeed, a substantial part of the argument about the validity of cranial work over the past 90 years has revolved around the problem of the SOJ and how its anatomy does not reflect cranial descriptions of motion. It is reassuring to me as a cranial practitioner that a careful analysis of the morphology of the cranial bones reflects my experience of externally palpated cranial motion. It also matches Sutherland and Magoun's descriptions of cranial motion, *provided that we ignore the "SBS"*. Sutherland's "SBS Lesions" remain a logical way to describe complex combinations of shear and rotation in three orthogonal planes and axes. From Sutherland originally taking them up as a systematic means to describe motion, they came to be thought of as having a physical reality of their own. If we drop the illusion of motion at the SOJ, they may be viewed as an extremely helpful map to a complex set of motions in 3D – rather than being the territory.

5.8.3 Behind the curtain

The comments made above with regard to clinical practice really just skim the surface, and are not intended to be taken as definitive. I have always found that the best way to practice cranial techniques is to exercise curiosity alongside a deep respect for the wisdom that resides in the body. In order to do this, we have to expect as little as possible – preferably to the extent of having no expectation at all of what we might be shown. The difficulty with learning a structured set of (e.g.) bony relationships and movements is that this movement can become an expectation in its own right. Here is the paradox – if there is no learning, there is insufficient structure to be able to comprehend and interact with what is being sensed. But learned facts can become expectations and then restrict what we are able to experience, or even create illusions.

5.8.4 Politics etc.

It is frustrating that the SOJ and its motion at the level of the CRI is a very tiny fraction of what cranial work is all about, and yet its anatomical impossibility is one of the arguments used to consign cranial work to the non-medical weird and wacky box. Initially, when I started researching in 2001/2 I was attempting to identify the physiological mechanism(s) for the CRI. The SOJ became a side issue that has proved to have something of a life of its own. Self-publishing in a peer reviewed journal from outside an academic institution is a huge task,

³⁰ https://en.wikipedia.org/wiki/Alfred_Korzybski

partly due to lack of funding, partly due to no free or easy access to many journal references (there were monthly to bimonthly journeys to the British Library for about 2 years), partly due to the lack of support through most of the process. I have made a clear decision not to repeat this (and therefore not peer-review publish a full reply to Richard Starkey's paper) because I simply do not wish to devote another two years of my life to the task of jumping through all the hoops.

For those reviewers who were hostile to what is being written here because they considered this to be an attack on Sutherland... AT Still asked us to “dig on”, and I find it hard to imagine that he or Sutherland or Harold Magoun or any of their contemporaries (or John Upledger, for that matter) would have wanted every single word they wrote to be engraved in tablets of stone. The title “Cook vs Sutherland” on one section of Starkey is slightly unfortunate. This is really not anyone against anyone else. It is about providing a more coherent foundation for the more physiological end of cranial work. There is a touch of hubris in quoting Newton's phrase “standing on the shoulders of giants”, but that is what is intended here. There is necessarily some criticism of the authors of cranial texts after Magoun who took his description of axes of rotation and translated that into a progressively more and more consolidated model of rigid mechanics that defy anatomy. But they too were standing on somebody's shoulders. And the SOJ mechanics actually constitute a tiny fragment of their otherwise positive contribution to cranial work.

6. CONCLUSIONS

So does the SOJ move in the manner suggested by the “Sutherland Lesions”? Physically, the clivus is very difficult to deform when compared to the immediately adjacent structures – the sphenoidal sinus and the superior orbital fissures.

Arising from a model of a relatively immobile SOJ and patent flexibility of other cranial structures according to Wolff's Law (and to FFF) - *palpated cranial motion may be described in a straightforward manner consistent with known anatomy, physiology and biomechanical principles*. As a practitioner, here I have to let out a “whoopeee” :-)) In this case, rather than being taken literally, the Sutherland Lesions are a useful and elegant way to map complex 3D distortions in the cranium. i.e. they are a map, and not the territory.

On the other hand, if we insist that the SOJ has to move (and continue to insist that the map **is** the territory), then our current knowledge of anatomy and physiology provides no simple means to describe either the full phenomenological range of palpated cranial motion, or explain the other issues and contradictions I have described above. :-(

Personally, as a general principle, I feel that Occam's razor can lead to category errors when applied to complex living systems, because they

- often exhibit spare capacity in the form of redundancy, so there is always an open question as to what there that is not manifesting
- often exhibit temporary synchronicity and resonance of quite distinct systems, which Occam-based interpretations confuse as being a single process
- use multiple and parallel means of communication

However, I see no good reason to choose complexity (insistence on unknown physiological mechanisms) over simplicity in this specific case – for all of the reasons listed above, particularly in section 4.

These conclusions also beg many questions regarding the nature of the driving mechanism for the CRI and the longer cranial rhythms – a far larger and yet more complex topic. Several of the observations above also conspire to indicate that (i) the CRI is not driven by change in CSF pressure, and (ii) the CRI is not necessarily driven by a mechanism that resides solely in the head (or even one that resides at all in the head). These points will be covered in detail in a future paper : please see <http://www.hummingbird-one.co.uk/resources2.html>

7. PRIMARY REFERENCES

(Further secondary references are embedded in the document as footnotes)

1. Starkey, R (2015) Arguments for and against movement at the spheno-occipital synostosis: Furthering the debate. *International Journal of Osteopathic Medicine* 18(2), pp102–115 doi: <http://dx.doi.org/10.1016/j.ijosm.2014.12.001>
2. Cook (2005) The mechanics of cranial motion—the sphenobasilar synchondrosis (SBS) revisited. *Journal of Bodywork and Movement Therapies* 9(3), pp177–188 doi: <http://dx.doi.org/10.1016/j.jbmt.2004.12.002> also available at http://www.hummingbird-one.co.uk/pdf/sbs_JBMT.pdf
3. Magoun, HI (1951) *Osteopathy in the cranial field* (1st edition). Reproduced by Sutherland Cranial Teaching Foundation (1997) ISBN: 193029803X
4. Sumner, G & Haines, S (2011) *Cranial Intelligence: A Practical Guide to Biodynamic Craniosacral Therapy* Paperback. Publ. Singing Dragon ISBN 184819028X
5. Ferguson, A (2003) A review of the physiology of cranial osteopathy. *Journal of Osteopathic Medicine* 6(2) pp74-88, with comment by Leon Chaitow. [http://dx.doi.org/10.1016/S1443-8461\(03\)80017-5](http://dx.doi.org/10.1016/S1443-8461(03)80017-5), available online as <http://faculty.une.edu/com/jnorton/PDFfilesCranial/CranialPhysiology.pdf>
6. Farasyn, A (1999) New hypothesis for the origin of cranio-sacral motion. *Journal of Bodywork and Movement Therapies* 3(1) pp229-237 doi: [http://dx.doi.org/10.1016/S1360-8592\(99\)80009-6](http://dx.doi.org/10.1016/S1360-8592(99)80009-6)
7. LoGerfo SE, Richardson ML, Dalley RW & Anzai Y (2015?) *Interactive Sinus Anatomy*, University of Washington Department of Radiology, Seattle, Washington : Normal Sphenoid. <http://uwmsk.org/sinusanatomy2/Sphenoid-Normal.html>

APPENDIX : A

A Brief verbal description of cranial bone motion with a fixed SOJ

Caveat : these really have to be worked out from anatomy and palpated – do NOT just rely on the following description! Clearly a lot of detail and important relationships to membranes and other features is missing. But most of the rest of the detail is correct (as near as dammit) in most standard cranial texts.

The motions of the bones here is largely based on the *form* of the body of the bone – i.e. its lability. The form of the sutures can be seen to match this pattern of motion. In this short description I have not matched the sutural forms to the relative motions, but you will see on examination of a hand specimen that they do match very well. Also, for brevity, there is almost no consideration of the cranial membranes. The relationship between membrane and bone also follows FFF, so as one part of the membranes becomes slack, another part will be tightened and take up the available slack immediately. If you remember that the bones, membranes (and everything else) have co-developed, so their motions will all be intimately connected through their form and biomechanical properties. Therefore, just as AT Still used to study bones to understand the working of muscles, we can do the same with the cranial bones to understand the role of the falx and tentorium.

All descriptions below are of a motion **into Flexion**. As a Fulcrum, the SOJ contains an internal strain as a result of these movements, but otherwise is relatively static. The exact loading on the SOJ/clivus needs to be confirmed by a finite element model of the cranium, but my analysis in lieu of that definitive work is that the clivus/basilium holds A-P compression.

Note that it is impossible *NOT* to use words like axis and hinge when describing these motions... However, the axis and hinges I describe are less inexact approximations than the ones usually seen in textbooks.

If anyone has any comments on these I would be very happy to hear from you.

1. Sphenoid

This bone contacts all the other bones of the cranial vault and most of the faciomaxillary complex, so it remains a pivot and a fundamental access route to any work with the head. The anterior part of the sphenoid (the sinus) complies, resulting in the anterior part of the inferior basilar surface rotating superiorly around the more solid hinge line of the solid sphenoidal body. See diagrams in the text and in Cook (2005). The superior orbital fissures close, and

therefore the greater wings are pulled inferiorly and slightly anteriorly. While this happens, the prongs of the sella turcica are opened, thus opening the pituitary. The pterygoid wings, sitting on the base of the sinus also flare outwards, hence the expansion of the posterior maxilla during Flexion. And the sinus also expands laterally, thus allowing the greater wings to reach out laterally. The anterior surface of the sphenoid sinus has to move more anteriorly, but is contained by its contact with the frontal and the lesser wings. Therefore, in the same way that the posterior edge of the vomer hinges on the basillium, the superior edge of the ethmoid hinges on the sella turcica as the inferior ethmoid is pushed anteriorly.

2. Temporals

The body of the temporal bone is so massive that it cannot flex. It is triangular in a sagittal section, with the apex being connected to the tentorium. As the greater wing moves forwards, the temporal bone rocks around the axis of its body (!!). This rocking motion very slightly changes the angle between the sphenoid and occiput in their continuity across the cranial base. See diagram in Cook (2005) The flaring occiput also pushes the posterior edge of the temporal laterally, so we have the classic “wobbly wheel” motion. The temporal squama is contained by the periosteum and dura and so has to stick to the parietal surface. However, because the parietals are flaring superiorly, the squama has to flex into a more angled shape. It also shifts its position relative to the temporal bone (hence Sutherland's “gills of a fish”). So there are no blood vessels on the internal surface of the cranium passing through this line of motion.

3. Parietals

The parietal is like a knotted handkerchief – a dome with four corners. If one corner goes down, the opposite corner also goes down, and the two other corners move up. So during flexion the corner against the greater wing follows the greater wing as it swings inferiorly and expands outwards, so this corner moves (more or less) away from the SOJ. Therefore the opposite corner moves similarly (roughly superiorly), allowing the occipital plate to swing anteriorly. At the same time, the corners at the bregma and against the posterior temporal squama move towards the SOJ. Thus the bregma moves inferiorly - this is a very very small motion because most of the motion of these two corners occurs by the posterolateral corner of the parietal as it displaces the gap left by the (anteriorly moving) posterior edge of the temporal bone.

4. Occiput

This is a very solid dish-shaped bone – its main option for motion is to bend along a lateral axis passing posterior to the condyles. And it is another four-cornered dome. Given that the body is fixed, the occipital plate/lambda swings towards the SOJ during Flexion. At the same time the posterior plate flares slightly out and away from the SOJ, becoming slightly less dish-shaped, thus following the temporals and parietals laterally.

5. Frontal

If you inspect a disarticulated frontal bone, you can see that it is a bowl with a flat base. The flat base (most of which is the superior part of the eye sockets) is very thin in places, but contains quite a few features which look like stiffening ridges. In particular, the anterior edge (where the bowl of the forehead meets the flat of the superior optic surface) and lateral corners (which take load from the ends of the greater wings – see Fig 1) are extremely strong. The only point of weakness is the cribriform plate and notch, and so the only possibility the frontal bone has is to flare out from this point. Thus, the metopic suture is a potential hinge line and tends to fuse first mid-forehead, with that fusion spreading superior and inferior as the frontal becomes less mobile. So the frontal is relatively static, and has to remain attached to the parietals – hence the need for the parietals to underlap at the bregma but overlap the lateral coronal suture. The parietals are just just far more flexible than the dome of the frontal and the line of its coronal suture. The frontal is essentially moved around by the other bones and is capable of just a small amount of lateral flaring. It hinges on the coronal suture. As the ethmoid notch expands, the angle between the floor and the dome increases, resulting in the frontal dipping forwards and down.